

What's your diagnosis?

Signalment: 9 year old MC 2.7 kg Papillion

Presenting Complaint: Presented for work up of anorexia and vomiting

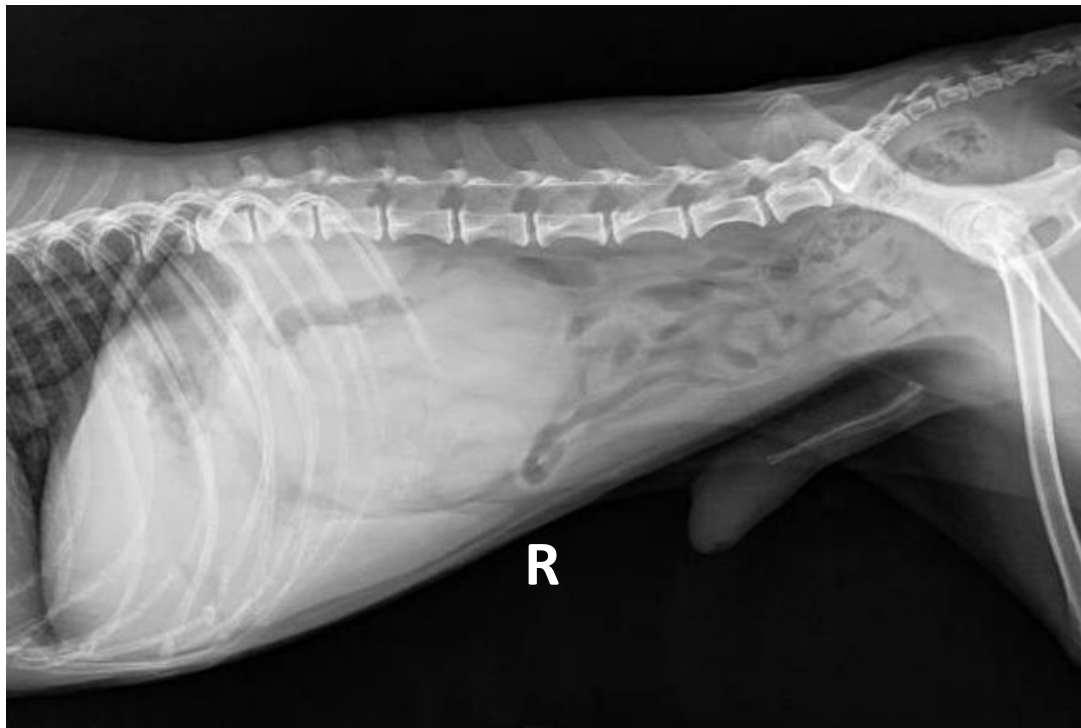
History: He had presented to cardiology for work up of a grad IV/VI heart murmur and congestive heart failure diagnosed 7 days ago by the referring veterinarian. At that time he had a history of tracheal collapse, dental disease, mild exercise intolerance, and active anorexia and daily vomiting of foam and bile. Blood work from the referring veterinarian was unremarkable, and the referring veterinarian had prescribed Pimobendan 1.25 mg ½ tablet BID. He was diagnosed by the cardiologist on echocardiogram with stage B1 endocardiosis (myxomatous valvular disease) and it was recommended to monitor for heart enlargement, continue the Pimobendan at the same dose regimen, and further diagnostics for cause of anorexia and vomiting.

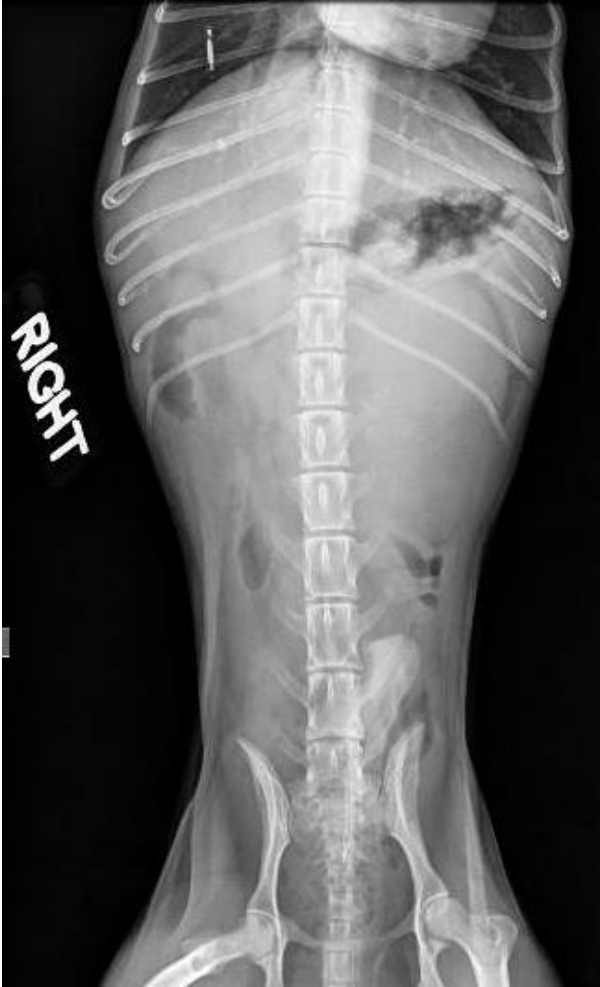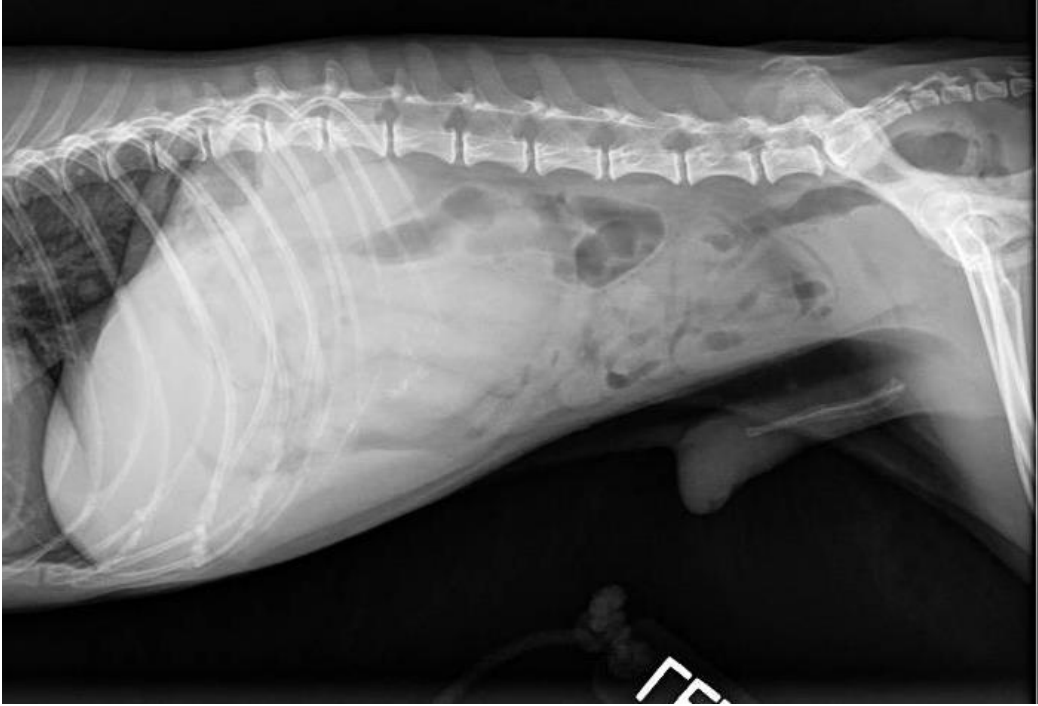Physical Exam Findings:

- BAR
- Mild bilateral lenticular opacity
- Moderate dental calculus on all arcades
- Grade IV/VI holosystolic murmur with strong, synchronous pulses
- Firm, round mass palpated in mid-cranial abdomen

Blood Work Abnormalities: None

Imaging and interpretations:



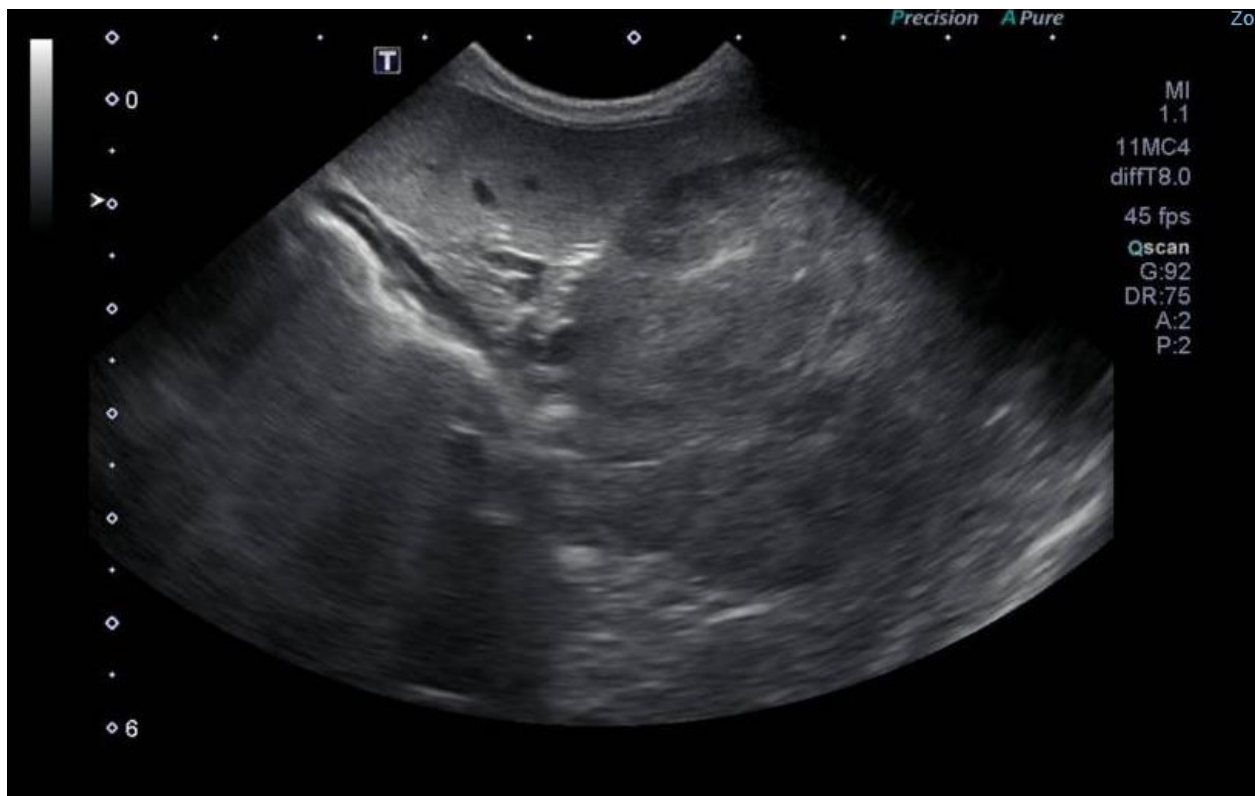

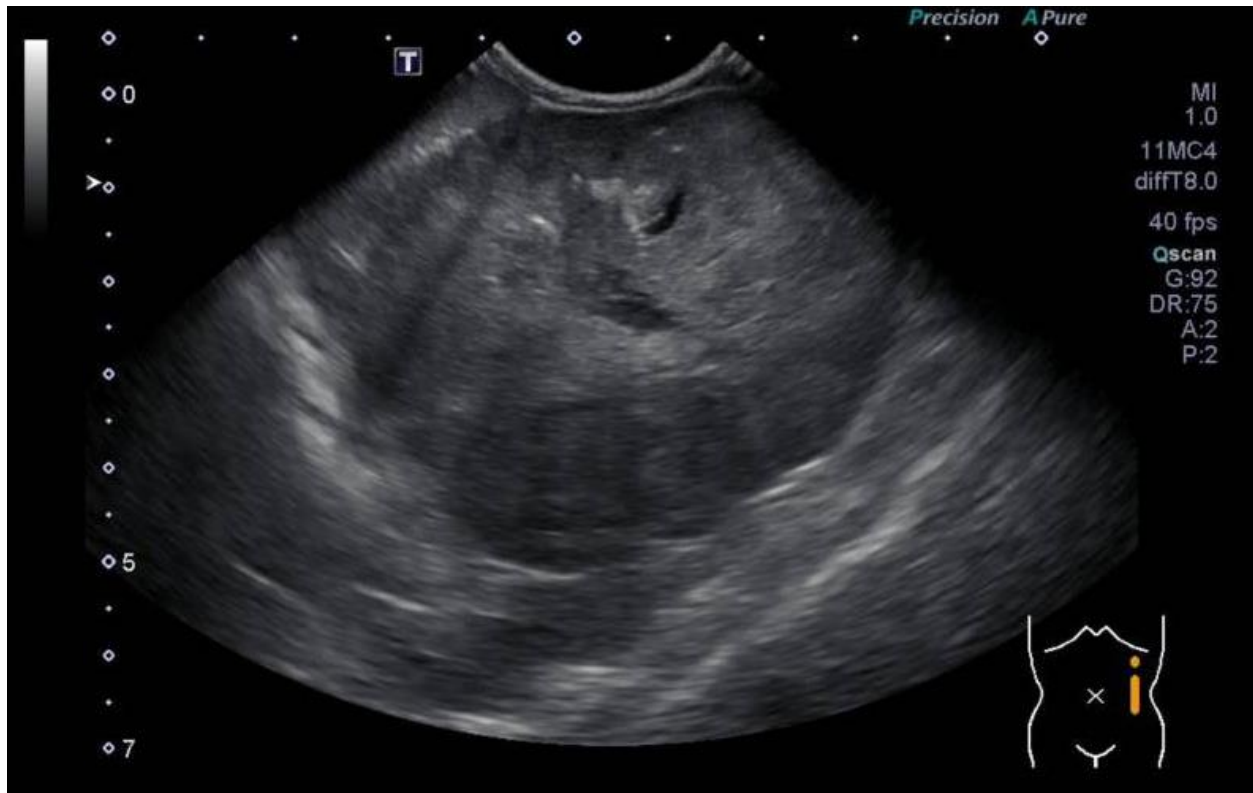Radiographic Findings of 3 view abdomen:

Musculoskeletal structures are normal. The abdominal serosal detail is adequate and the contour is normal. There is a round to ovoid, soft tissue opaque, well marginated mass in the left, cranial, dorsal abdomen causing ventral, right, and caudal displacement of the small intestines. It expands from cranial T13 to mid L4 in length and 3/4ths of the abdominal height going from the ventral vertebral bodies down to contact the splenic tail. There are numerous, granular, mineral opacities superimposed over the middle and ventral aspects of the mass. The bladder is not visualized.

Radiographic Interpretations:

The soft tissue mass with granular mineralization is most consistent with the left kidney with differential diagnosis of primarily neoplasia or lesser consideration to unilateral hydronephrosis, perinephric fluid, cystic disease, inflammatory disease, and hematoma. Recommend abdominal ultrasound with potential fine needle aspiration of the mass if possible and thoracic radiographs.





Abdomen Ultrasound Findings:

The gallbladder contained suspended and gravity dependent hyperechoic and echogenic debris. There was a heterogeneous, mixed echogenicity mass measuring 6.4 x 4.7 cm in dimension in the region of the left kidney. A normal left kidney was not identified. This mass did not have any identifiable normal renal architecture. There were multiple shadowing hyperechogenicities measuring up to 10.6 mm in length within the mass. The left adrenal gland measured 3.6 mm in thickness. The right adrenal gland measured 5.2 mm in thickness. The liver, spleen, right kidney, left and right adrenal glands, urinary bladder, prostate, gastrointestinal tract, and pancreas were within normal limits.

Ultrasound Impressions:

Left renal mass with mineralization is consistent with neoplasia. Gallbladder sludge.

Ultrasound-guided procedure:

Fine needle aspirates of the previous described left renal mass were obtained without immediate complication.

Cytology of FNA of renal mass:

Epithelial cell neoplasia -- given the presence of acinar-like structures cytologic findings are most suggestive of a nephroblastoma or renal adenocarcinoma. However, other carcinomas can't be ruled out. Histopathology is strongly recommended for confirmation.

Diagnostic Plan:

This patient's renal mass was diagnosed as either a nephroblastoma or renal adenocarcinoma of the left kidney. This tumor may be the cause of his anorexia and vomiting due to abdominal discomfort and increased pressure on his other organs. I recommend thoracic radiographs to check for metastatic neoplasia, surgically removing the left kidney, and submitting it for histopathology for a definitive diagnosis and to plan further chemotherapy treatments. Carboplatin would be the chemotherapy agent of choice or secondarily toceranib (Palladia). The prognosis for patients with renal adenocarcinoma or nephroblastoma treated with surgery alone is overall good with a reported survival time of years after surgery. The specific prognosis for patients with metastatic renal adenocarcinoma is unknown since there are no published reports of response to chemotherapy alone.