

“What’s Your Diagnosis?”

Signalment:

Species: Canine
Breed: Retriever/Golden/Mix
Sex: Male Castrated
Date of Birth: 11/01/98

Presenting Complaint:

- Unable to urinate for previous 4 days – spent this time at rDVM
- Owner reported history of stranguria leading to eventual anuria
- Tarry, dark-colored stool
- Previous 4 month history of progressive weight loss – 20 lb weight loss total

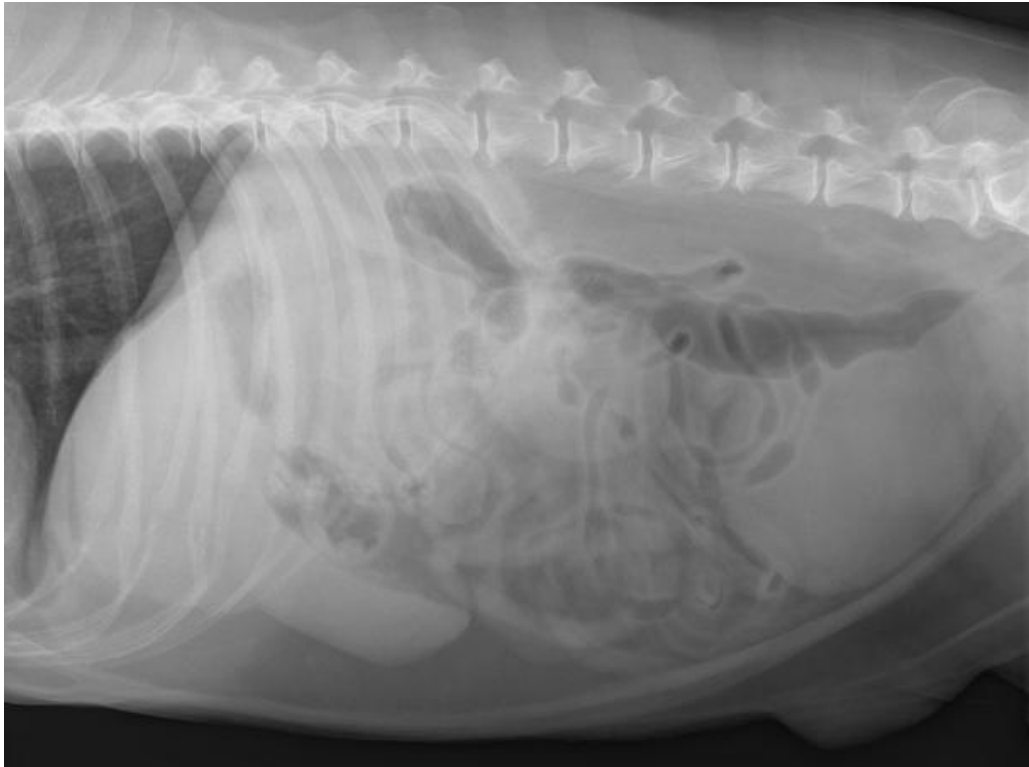
Physical Examination:

- Abdominal palpation revealed a large, distended bladder
- Rectal examination revealed a painful, enlarged prostate as well as smooth subiliac lymph node enlargement
- No melena noted during rectal examination
- No abnormalities in temperature, pulse, respiratory parameters

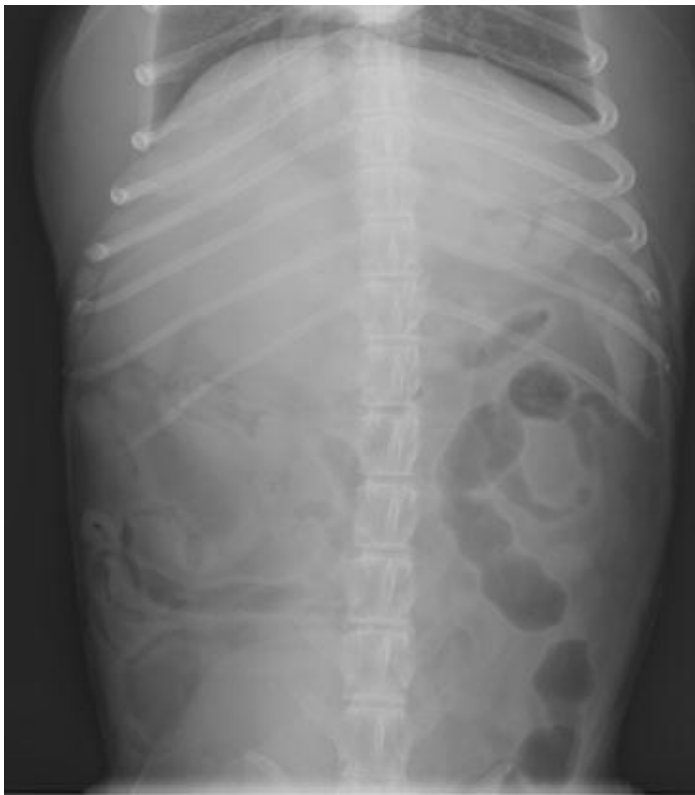Diagnostic Plan:

1. Abdominal radiographs
2. Abdominal ultrasound
3. Urinary catheterization and collection of urine for cytology

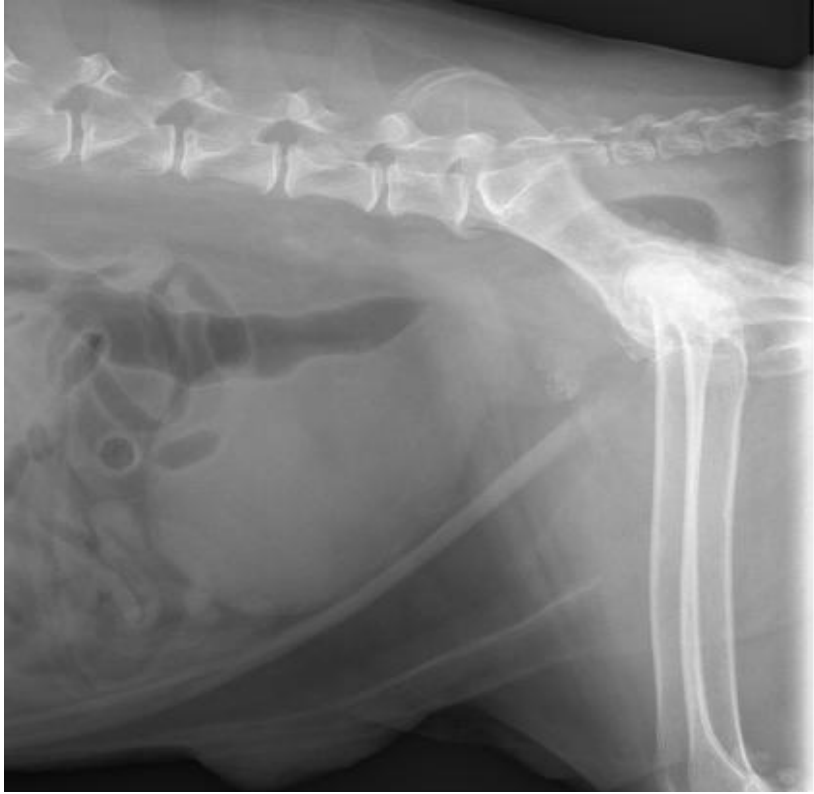What are your initial radiographic and ultrasonographic impressions?



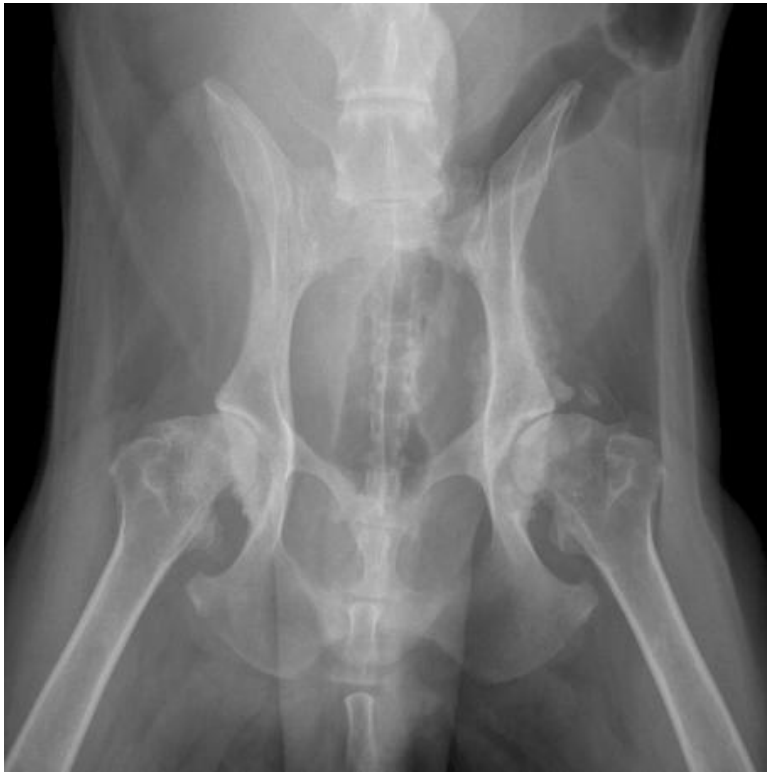Right Lateral Cranial Abdomen



VD Cranial Abdomen



Right Lateral Caudal Abdomen



VD Caudal Abdomen

Prostate ultrasound images:

