

What's Your Diagnosis?

Signalment:

Anne RCHS

Species: Canine

Breed: Coonhound/Bluetick Mix

Sex: Intact Female

DOB: 05/01/2008

History At presentation puppy was half the size of her littermates. She was less active and anorectic. The puppy vomited digested food once and had diarrhea previously. Tested "Neg" with ELISA for parvovirus. She had one booster of DHPP vaccine a week ago.

Physical Exam: T – 100.0 °F, P – 168 bpm, R – 30 bpm QAR, 5-7% dehydration.

- Respiratory system: Cough, bilateral mucoid nasal discharge and increased lung sounds were present.
- Cardiovascular: systolic grade 3 out of 4 heart murmur

Plan:

Thoracic radiographs.

CBC:

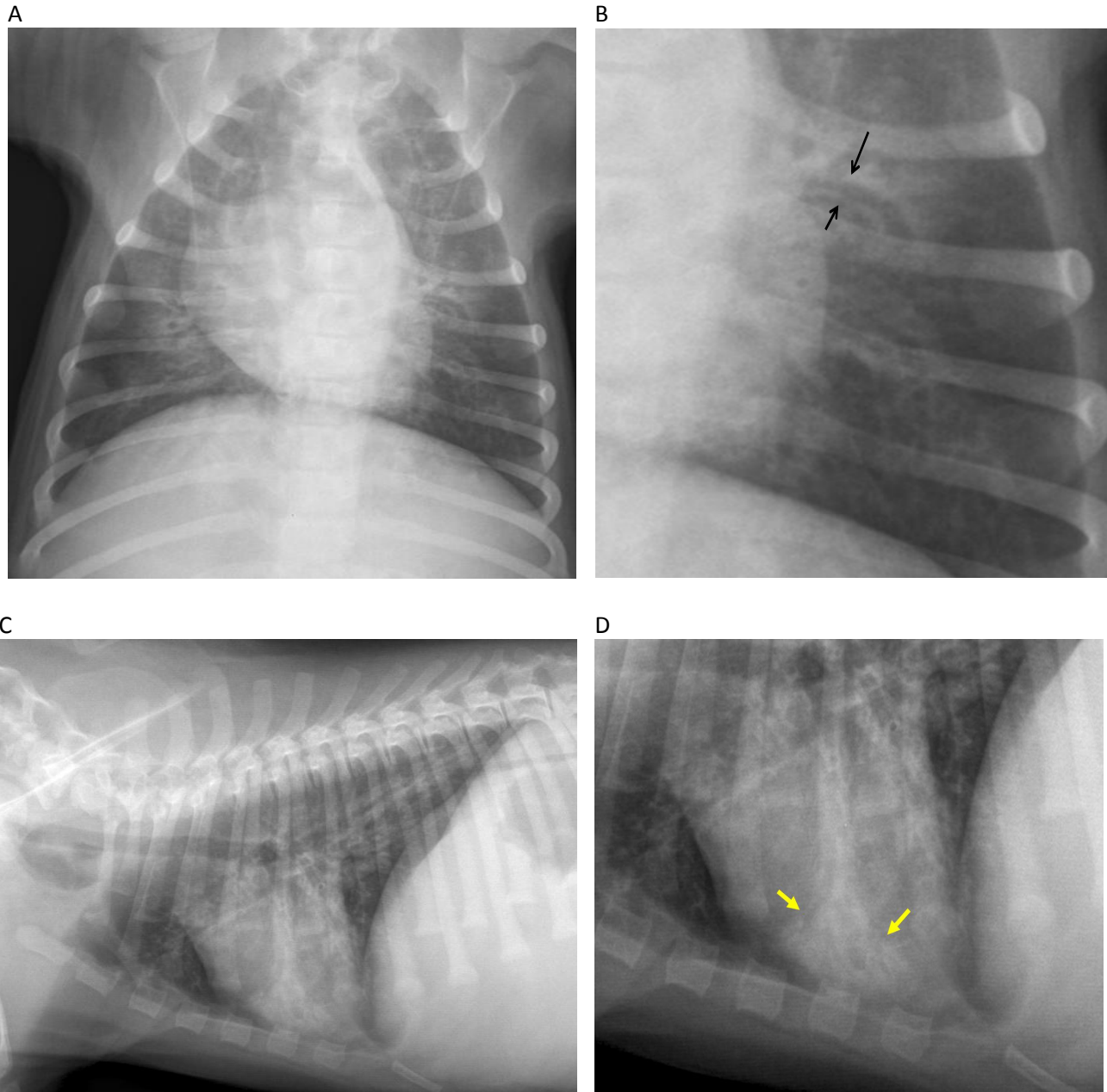
- Anemia: PCV - 34%.0 (polychromasia and anisocytosis)
- Monocytosis – 1.3 K/uL

Chemistry:

- Creatinin – 0.2 mg/dL (↓)
- Albumin – 2.5 g/dL (↓)
- TP – 5.0 g/dL (↓)
- Phosphorus – 7.3 mmol/L (↑)
- Sodium – 142 mmol/L (↓)
- Chloride – 98 mmol/L (↓)
- Alanine transaminase – 26 U/L (↓)
- CK – 359 U/L (↑)

Conjunctival swab IFA "+" for distemper virus

Survey Radiographs:



A - Ventrodorsal view; B - Bronchial pattern in the left caudal lung lobe (arrows – thickened bronchi between the arrows); C - Right lateral view; D – Caudal part of the left cranial lung lobe (alveolar pattern between the arrows)

Interpretation:

Lung changes consist of mixed interstitial, bronchial and alveolar patterns. Diffuse interstitial pattern is overlaid by irregular areas of alveolar pattern at the caudal part of the left cranial and right middle lung lobes. Bronchial pattern is present in the right and left cranial, and left caudal lung lobes. Bronchi appear thickened and irregular.

Air distended esophagus is present in the caudal cervical region ventrally to the trachea.
Stomach is filled with fluid and gas.

Heart appears normal in size, shape, margins and location.

Conclusion

- ✓ Aerophagia
- ✓ Bronchopneumonia: rule out infectious, allergic and immunologic causes