

What's Your Diagnosis?

Signalment:

Anne RCHS

Species: Canine

Breed: Coonhound/Bluetick Mix

Sex: Intact Female

DOB: 05/01/2008

History At presentation puppy was half the size of her littermates. She was less active and anorectic. The puppy vomited digested food once and had diarrhea previously. Tested "Neg" with ELISA for parvovirus. She had one booster of DHPP vaccine a week ago.

Physical Exam: T – 100.0 °F, P – 168 bpm, R – 30 bpm QAR, 5-7% dehydration.

- Respiratory system: Cough, bilateral mucoid nasal discharge and increased lung sounds were present.
- Cardiovascular: systolic grade 3 out of 4 heart murmur

Plan:

Thoracic radiographs.

CBC:

- Anemia: PCV - 34%.0 (polychromasia and anisocytosis)
- Monocytosis – 1.3 K/uL

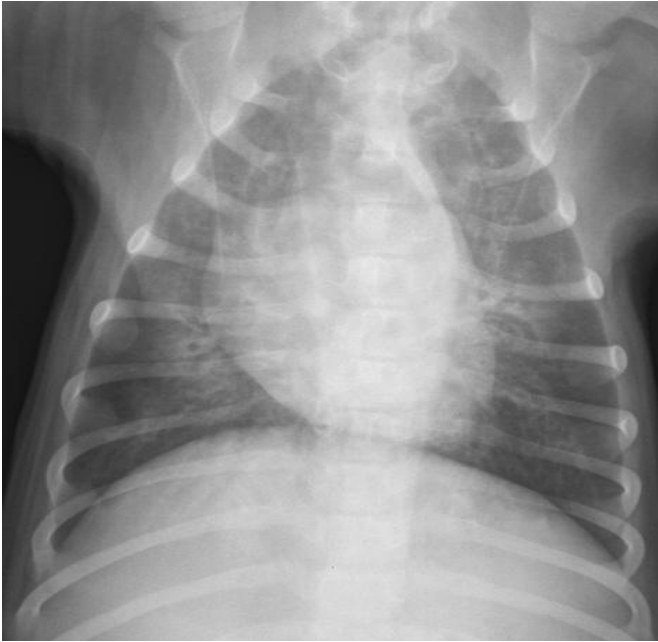Chemistry:

- Creatinin – 0.2 mg/dL (↓)
- Albumin – 2.5 g/dL (↓)
- TP – 5.0 g/dL (↓)
- Phosphorus – 7.3 mmol/L (↑)
- Sodium – 142 mmol/L (↓)
- Chloride – 98 mmol/L (↓)
- Alanine transaminase – 26 U/L (↓)
- CK – 359 U/L (↑)

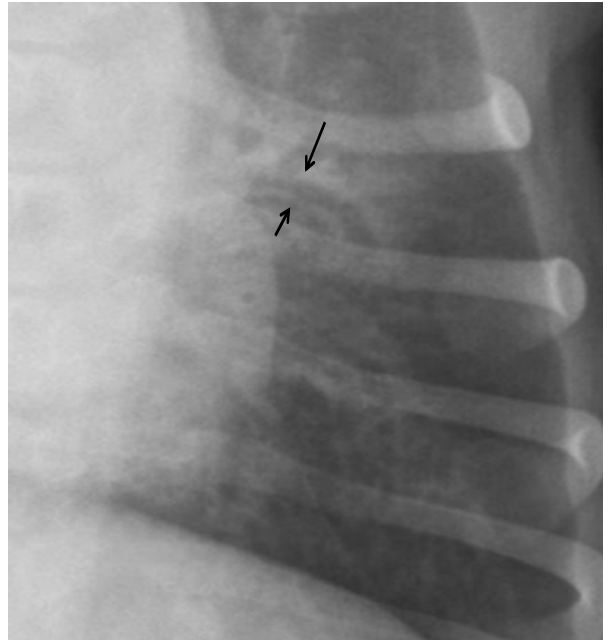
Conjunctival swab IFA "+" for distemper virus

Survey Radiographs:

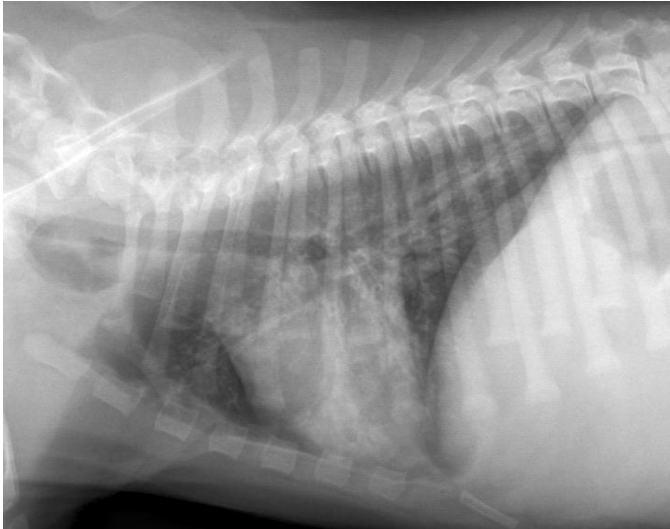
A



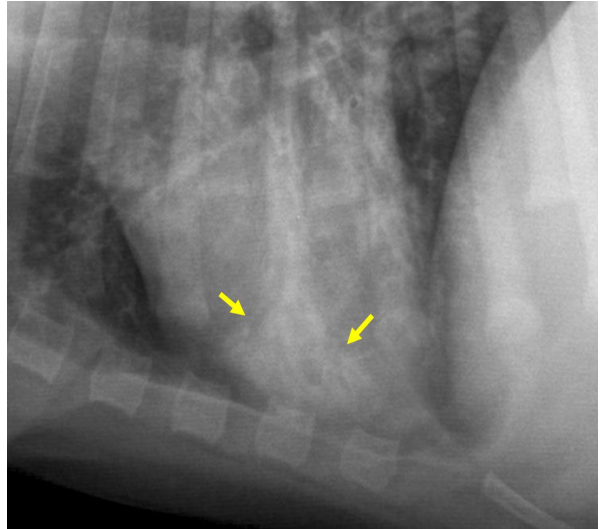
B



C



D



A - Ventrodorsal view; B - Bronchial pattern in the left caudal lung lobe (arrows – thickened bronchi between the arrows); C - Right lateral view; D – Caudal part of the left cranial lung lobe (alveolar pattern between the arrows)